Correcting Eyelid Ptosis with Botulinum Toxin: A Case Study

Introduction

- Lid ptosis is a condition where the upper eyelid droops due to weakened or overstretched eye muscles[1]
- It occurs when the muscles responsible for lifting the eyelid, the levator palpebrae superioris and the superior tarsal (Müller's muscle), weaken or become stretched
- Toxin-induced ptosis typically resolves on its own but may cause temporary distress to patients.
- We used pre-tarsal BoNT-A injections, as described in the Journal of Clinical Aesthetic Dermatology[2], for ptosis treatment.
- The hypothesis is that BoNT-A injections target the pre-tarsal orbicularis muscle, promoting eyelid retraction.[2]
- We administered prabotulinumtoxinA-xvfs (known as Jeuveau in the US and Nuceiva in Europe and Canada)[3-7]
- While all brands of toxins perform in a similar way, there are some nuances with the products.[8]
- We chose prabotulinumtoxinA-xvfs for its perceived precision and tighter diffusion, noting this is based on our anecdotal experience

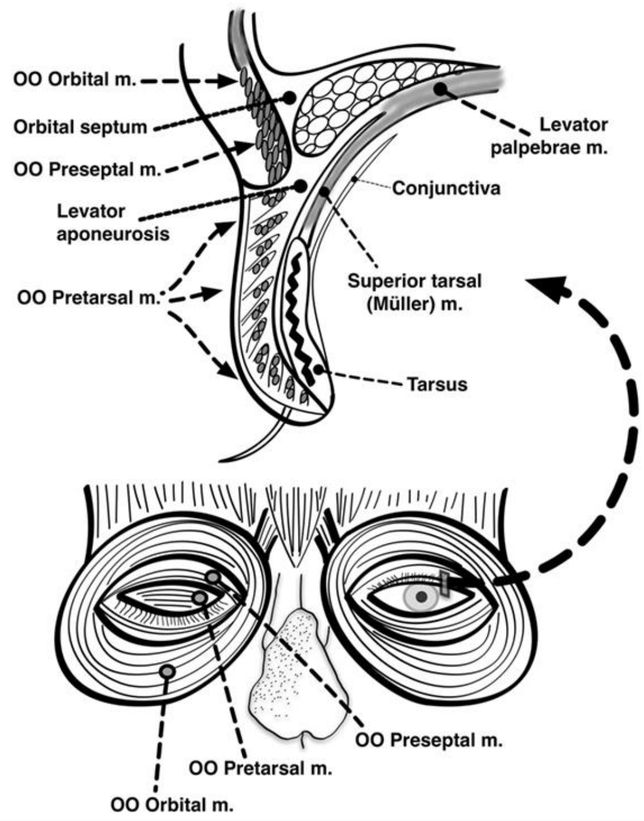

Hamster-induced ptosis case study by Dr Parys



Background:

- A 34-year-old female sought correction for trauma-induced eyelid ptosis stemming from a childhood injury caused by a hamster
- Surgical correction had been explored but deemed unsuitable as there was no excess skin
- Initial attempts with filler showed limited success, prompting exploration of a pre-tarsal toxin technique

Treatment:

- 2 units of prabotulinumtoxinA-xvfs was injected transdermally 2mm above the lash line in the medial and lateral third of the pre-tarsal orbicularis[2], employing a concentrated solution of 50u in 0.5ml for an even tighter field of effect[9]
- Notable improvement was observed just three days post-treatment, underscoring the potential of toxin use in managing traumatic ptosis, with ongoing maintenance every 3-6 months

Toxin induced ptosis case study by Dr Land

Background:

- A colleague developed left-sided lid ptosis after BoNT-A injections for migraines. Despite the cosmetic side effect, NHS advice was to tolerate it due to the treatment's effectiveness
- Interested in an alternative solution, she inquired about apraclonidine eye drops
- However, I suggested a novel intertarsal toxin injection technique we hadn't yet employed in our clinic, using prabotulinumtoxinA-xvfs, known for its limited diffusion

Treatment:

- 0.5 units were injected in each side transdermally 2mm above the lash line in the medial and lateral limbal lines, into the pre-tarsal orbicularis.[2]
- Notable improvement was observed in just 2 days, resolving the ptosis without further interventions



Conclusion:

- Pre-tarsal BoNT-A injections show potential in treating eyelid ptosis, with observed cosmetic improvements in both toxin and trauma cases
- Both patients saw an improvement in eyelid ptosis, resulting in an improvement in cosmetic appearance within a few days

Authors: Dr. Alexander Parys — Dr. Steven Land
Contact Details: contact@sonuclinic.com — info@novellusaesthetics.co.uk
Affiliations: SONÜ Medical Aesthetics, UK — Novellus Aesthetics, UK
Declaration of Conflict of Interest: None

@DOCTORALEXUK @DOCTOR_LAND

References:
1. Shahzad B, Siccardi MA, 'Ptosis', StatPearls. Treasure Island, 2023. 2. Mustak H, Rafaelof M, Goldberg RA, Rootman D, 'Use of Botulinum Toxin for the Correction of Mild Ptosis', J Clin Aesthet Dermatol, 2018. 3. Beer KR, Shamban AT, et al., 'Efficacy and Safety of PrabotulinumtoxinA for the Treatment of Glabellar Lines in Adult Subjects: Results From 2 Identical Phase III Studies', Dermatol Surg, 2019. 4. Ogilvie P, Jones DH, et al., 'PrabotulinumtoxinA for Treatment of Millennials With Moderate to Severe Glabellar Lines: Post Hoc Analyses of the Phase III Clinical Study Data', Dermatol Surg, 2022. 5. Rzany BJ, Ascher B, et al., 'A Multicenter, Randomized, Double-Blind, Placebo-Controlled, Single-Dose, Phase III, Non-Inferiority Study Comparing PrabotulinumtoxinA and OnabotulinumtoxinA for the Treatment of Moderate to Severe Glabellar Lines in Adult Patients', Aesthet Surg J, 2020. 6. Solish N, Ascher B, et al., 'PrabotulinumtoxinA vs OnabotulinumtoxinA for the Treatment of Adult Males With Moderate to Severe Glabellar Lines: Post-hoc Analyses of the Phase III Clinical Study Data', Aesthet Surg J, 2022. 7. Gadarowski MB, Ghamrawi RI, et al., 'PrabotulinumtoxinA-xvfs for the Treatment of Moderate-to-Severe Glabellar Lines', Ann Pharmacother, 2021. 8. Kaminer MS, Cox SE, et al., 'Re-examining the Optimal Use of Neuromodulators and the Changing Landscape: A Consensus Panel Update', J Drugs Dermatol, 2020. 9. Kaminer MS, Cox SE, Fagien S, Kaufman J, Lupo MP, Shamban A. Erratum: Re-examining the Optimal Use of Neuromodulators and the Changing Landscape: A Consensus Panel Update. J Drugs Dermatol. 2020 May 1;19(5):S1545961620P0010X. Erratum for: J Drugs Dermatol. 2020 Apr 01;19(4):s5-15. PMID: 32243121.